



UNE Anesthesia Extra

UNIVERSITY OF
NEW ENGLAND

Brought to you by MSNA Class of 2015



Volume 2, Issue 7

JULY 2014



Get plugged in! This year the Nurse Anesthesia Annual Congress will be held in Orlando, FL. View the [program here](#).

Network with colleagues, participate in exciting events, learn the latest evidence-based practice from the front lines. [Click here for the event website](#).

See you there!
- Mark



Congratulations To the Class of 2016!

CERT EXAM REVIEW

Question #1
What are the indications for GPIIb/IIIa inhibitors?

Question #2
During mediastinoscopy, on which arm do you place a noninvasive blood pressure cuff?



Hypoplastic Left Heart Syndrome: Modification of Norwood Stage 1

Submitted by Kirstyn Indgjer SRNA

In 2003, a major modification to the modified Blalock-Taussig shunt (MBT) was introduced.

The RVPA, a shunt that connects the right ventricle to the pulmonary artery, was substitutes for the MBT, which carries blood from the brachiocephalic artery to the pulmonary artery.

In a study performed by the Pediatric Heart Network, these two surgical interventions were compared in 549 infants across North America. The result showed that the RVPA had greater survival at 12 months versus the MBT.

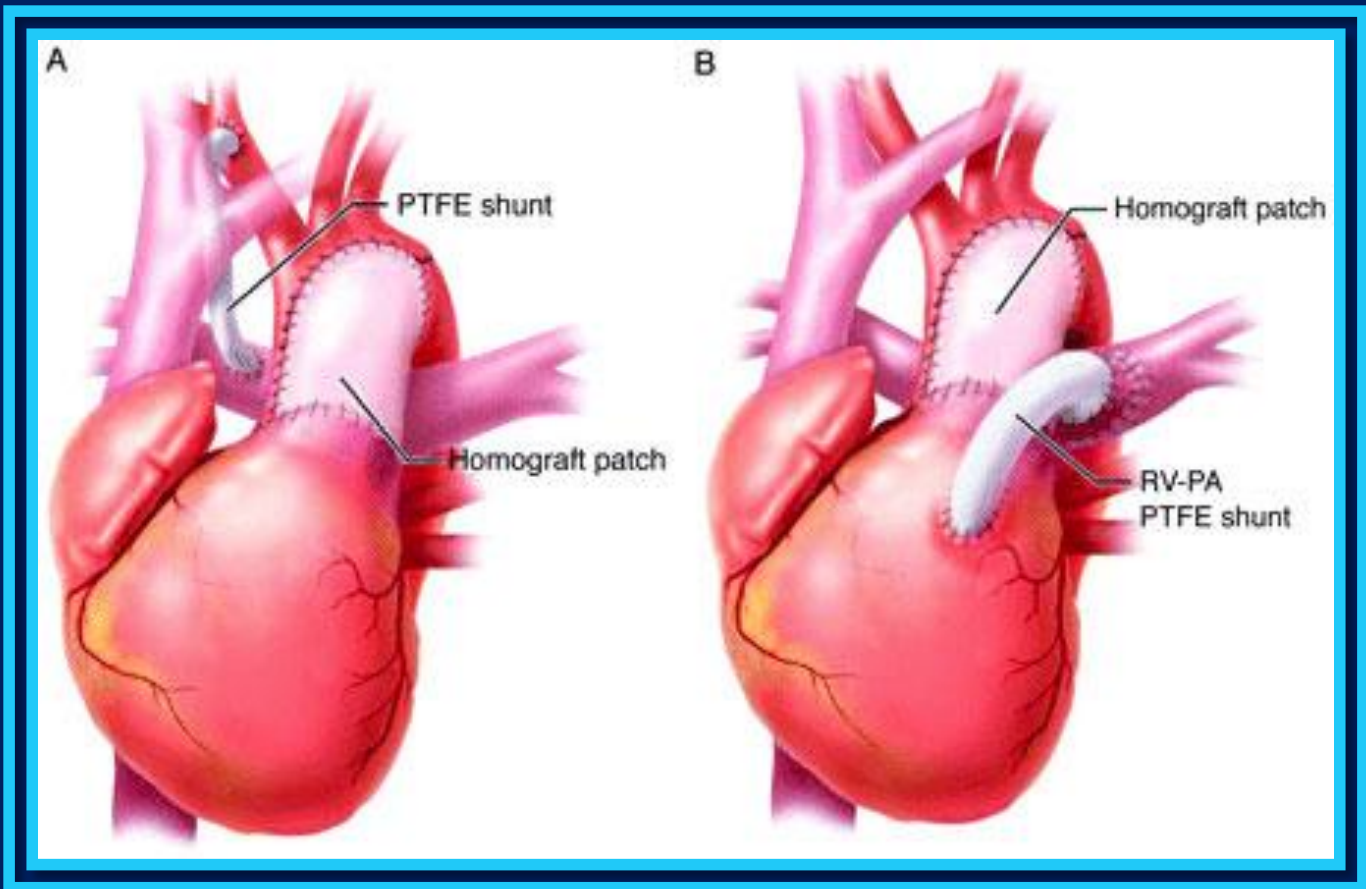
However, the advantages of the RVPA do not seem to be sustained over a 3-year period. Studies are currently in progress in attempts to identify the superior technique for children with HLHS.

Reference:

Rosenthal, D. (2014). Single ventricle reconstruction trial. *Circulation*, 129, 2000-1. Doi10.1161/CIRCULATIONAHA.114.009594

Answer #1

The GPIIb/IIIa antagonists have been used principally for the management of acute coronary syndromes and percutaneous coronary interventions (PCI). [Nagelhout & Plaus, *NA*. 4e, 2009 pp856t; Stoelting, *PPAP*. 4e. 2006 pp518f; Barash, *Clin. Anes.* 6e, 2009 pp399]



Answer #2

During mediastinoscopy, a noninvasive blood pressure cuff is placed on the left arm. A non-invasive blood pressure cuff on the left arm enables continual monitoring of systemic blood pressure during periods of innominate artery compression. [Nagelhout & Plaus, *NA*. 4e, 2009 pp647; Morgan, *et al.*, *Clin. Anesth.* 4e. 2006 pp607]